

Title: Objective Analysis of Toric Intraocular Lens Rotation and Centration

Running Head: Objective Analysis of Toric Intraocular Lenses

Authors: James S. Wolffsohn, PhD
Phillip J. Buckhurst, BSc

Affiliation (all authors): Aston University, School of Life and Health Sciences, Ophthalmic Research Group, Birmingham, B4 7ET, UK

Presentation: Association for Research in Vision and Ophthalmology meeting, Fort Lauderdale, May 2009

None of the authors has a financial or proprietary interest in any of the products, methods or materials mentioned

Corresponding Author:

Prof James S. Wolffsohn

Aston University, School of Life and Health Sciences, Ophthalmic Research Group

Aston University, Birmingham, B4 7ET, UK

Email: j.s.w.wolffsohn@aston.ac.uk

Abstract

PURPOSE: To assess the repeatability of an objective image analysis technique to determine intraocular lens (IOL) rotation and centration.

SETTING: Six ophthalmology clinics across Europe.

METHODS: One-hundred seven patients implanted with Akreos AO aspheric IOLs with orientation marks were imaged. Image quality was rated by a masked observer. The axis of rotation was determined from a line bisecting the IOL orientation marks. This was normalized for rotation of the eye between visits using the axis bisecting 2 consistent conjunctival vessels or iris features. The center of ovals overlaid to circumscribe the IOL optic edge and the pupil or limbus were compared to determine IOL centration. Intrasession repeatability was assessed in 40 eyes and the variability of repeated analysis examined.

RESULTS: Intrasession rotational stability of the IOL was ± 0.79 degrees (SD) and centration was ± 0.10 mm horizontally and ± 0.10 mm vertically. Repeated analysis variability of the same image was ± 0.70 degrees for rotation and ± 0.20 mm horizontally and ± 0.31 mm vertically for centration. Eye rotation (absolute) between visits was 2.23 ± 1.84 degrees (10% > 5 degrees rotation) using one set of consistent conjunctival vessels or iris features and 2.03 ± 1.66 degrees (7% > 5 degrees rotation) using the average of 2 sets ($P = .13$). Poorer image quality resulted in larger apparent absolute IOL rotation ($r = -0.45, P < .001$).

CONCLUSIONS: Objective analysis of digital retroillumination images allows sensitive assessment of IOL rotation and centration stability. Eye rotation between images can lead to significant errors if not taken into account. Image quality is important to analysis accuracy.

Toric intraocular lenses (IOLs) are becoming more commonly available, allowing more predictable, precise and stable correction of astigmatism than corneal/limbal relaxing incisions.^{1,2} Optimal astigmatic correction requires precise IOL axis alignment with the meridian of corneal astigmatism. As well as visual acuity, refraction and keratometry, studies tend to assess intraocular lens rotation subjectively,³ using a slit lamp biomicroscope eyepiece graticule⁴ or slit beam protractor,⁵ although this is often not specified.⁶ However, these subjective techniques rely on the patient maintaining a stable and vertical head position at each assessment and only estimate rotation to approximately the nearest one to five degrees.

Digital imaging has been applied to toric intraocular lens rotation assessment. The original studies used generic^{7,8} or bespoke image analysis software⁹ to assess the rotation of a line drawn to join features on the IOL. However, this axis was compared to the image horizontal plane, ignoring the effect of head or eye rotation between assessments.

The eyes rotational stability during photography has been assessed over at least 6 months using fundus image analysis and shown to change on average by 2.5° between visits, although it was as high as 11.5°, being greater in women, older patients and those with worse visual acuity or higher astigmatism.³ The authors noted that the deviation in the measured orientation of the eye between visits resulted from a combination of cyclotortion, head rotation and autorotation during fixation of the positioning light. They also estimated relatively large errors from the mounting of the camera and framing and projection of slides, which is less of an issue with slit-lamp integrated cameras. The latter usually have an external light source as well as the slit beam to allow illumination of the iris and bulbar conjunctiva at the same time as the retroillumination. They recommended a digital overlay technique that uses conjunctival vessels,

Axenfield loops or iris structure as references to account for these intrinsic rotations. Weinand and colleagues used this technique immediately and 6 months after IOL implantation in 17 of 40 eyes implanted with the AcrySof SA60AT.¹⁰ The other images could not be analysed due to insufficient dilation (IOL orientation required visibility of both haptic-optic junctions) and poor image quality. In addition, a different camera was used on each occasion and repeatability of analysis and image capture was not assessed. Patel and colleagues also compensated for head and eye rotation by rotating the retroilluminated image to align corneal ink markings demarked prior to surgery on a surgical video frame with the 6 o'clock position. This technique had an intraobserver variability of 2.3 to 3.1°.¹¹ Most recently, Shah and colleagues calculated the centre of the IOL as the centre of a rectangle with the toric IOL marks as the opposite corners.¹² They overlaid a radial grid on the centre of the IOL to assess the axis of a line joining the toric marks to 0.1 ° precision. The axis of a line joining the centre of the IOL to a single prominent episcleral vessel was used to compensate the image for eye and head rotation. However, this complex method is susceptible to error if the IOL changes centration.

Optimal alignment is a major issue if toric correction or compensation of ocular aberrations are intended to be incorporated into the IOL optic.¹³ IOL centration has been assessed by image analysis fitting an oval to the intraocular lens optic margin and the limbus and comparing the centres.^{8,14,15} However, the repeatability of analysis and image capture has not been assessed and although image quality was stated as an important factor, the effect of this poor image quality has not been determined.

This study, therefore, examines the repeatability of objective analysis of IOL rotation and centration and the effect of image quality.

Method

One hundred and seven patients implanted with the Akreos AO aspheric IOL with orientation marks in one eye at six hospital sites across Europe were dilated using phenylephrine 2.5% and tropicamide 1.0%. The intraocular lens was imaged at 10x magnification in retroillumination using a CSO SL-990 digital slit-lamp biomicroscope. This was repeated at 1-2, 7-14, 30-60 and 120-180 days after IOL implantation. Informed consent was obtained from all participants prior to lens implantation and the study was approved by ethical committees at each of the sites.

The axis of rotation of the IOL was determined by drawing a line to join the IOL orientation marks. This was normalised for any rotation of the eye in front of the slit-lamp between visits by comparing the axis of a line joining two consistent conjunctival vessels or iris features on opposite sides of the pupil margin (Figure 1). The reference markers needed to be visible on the images captured at every follow-up visit. The centre of ovals overlaid to circumscribe the IOL optic edge, the pupil margin and the limbus were compared to determine the IOL centration (Figure 1). The images were graded subjectively by a clinician masked to the IOL rotation and centration, who was familiar with digital slit-lamp imaging but who did not take part in the image capture. Iris feature quality including illumination consideration (poor/ungradable 0; moderate 1; good 2; excellent 3); scleral blood vessel clarity including illumination consideration (poor/ungradable 0; moderate/partially obscured markings 1; good 2; excellent 3); and toric IOL marking clarity including illumination and dilation consideration (at least one not visible 0; indistinct 1; clear 2; sharp 3) were rated.

Two images of each eye immediately after surgery were captured in forty patients and analysed to assess intra-session repeatability of the technique. Images from two patients were analysed 10 times to assess the repeatability of the analysis.

Statistical Analysis

Subjectively rated image quality elements and their relationship to apparent IOL rotation were compared with Spearman's rank correlation and between visits and sites with Friedman's Chi-Squared test. Head rotation, as assessed by one or the average of two sets of blood vessel or iris features on either side of the pupil, was compared with a t-test. Standard deviations are reported to assess the intra-session and repeated analysis variability in IOL rotation and centration.

Results

Overall, subjectively rated iris and blood vessel clarity were strongly correlated ($r = 0.487$, $p < 0.001$), and these assessments were related moderately to the clarity of the IOL axis marks ($r = 0.237$; $r = 0.184$ respectively, $p < 0.001$). The clarity of the blood vessels was rated best, generally increasing between visits (Friedman Chi-Sq = 14.782, $p = 0.002$; Table 1). Iris features were rated as least clear, with a counter tendency to decrease in clarity between visits (Chi-Sq = 7.349; $p = 0.062$) along with IOL axis marks (Chi-Sq = 10.811, $p = 0.013$; Table 1). The sites significantly differed in their ability to capture clear images of the blood vessels (Chi-Sq = 29.148, $p < 0.001$), iris features (Chi-Sq = 28.611, $p < 0.001$) and toric IOL marks (Chi-Sq = 19.677, $p = 0.001$).

Due to the relationship between blood vessel and iris feature clarity and the reliance on only one of these features to assess head rotation, the maximum score of these two ratings was taken. As inability to detect either these anterior eye features or the IOL toric marks resulted in an image that could not be graded, the two were multiplied and divided by the maximum possible value of 9 to give the percentage quality. The average image quality between the 1-2 days and 120-160 days after IOL implantation was significantly correlated to absolute apparent toric IOL rotation compensated for head movements ($r = -0.449$, $p < 0.001$; Figure 2).

Head rotation as assessed by the rotation of blood vessel or iris features on either side of the pupil between visits was similar if one ($2.23 \pm 1.84^\circ$; 10 % > 5° rotation) rather than the average of two ($2.03 \pm 1.66^\circ$; 7 % > 5° rotation) sets of markers were used ($p = 0.126$). Measured changes in IOL centration were similar whether compared to the pupil centre or limbal centre for

7-14days (0.24 ± 0.18 mm vs 0.20 ± 0.15 mm, $p = 0.152$), 30-60 days (0.24 ± 0.21 mm vs 0.27 ± 0.22 mm, $p = 0.147$) and 120-180 days (0.22 ± 0.17 mm vs 0.24 ± 0.19 mm, $p = 0.370$) compared to 1-2 days post surgery. However, the absolute difference in anatomical centre between the pupil and limbus varied greatly, being larger in the vertical (1.89 ± 1.82 mm) compared to the horizontal (0.18 ± 0.19 mm, $p < 0.001$) meridian.

The standard deviation of intra-session rotation of the IOL was $\pm 0.79^\circ$ and centration was ± 0.10 mm horizontally and ± 0.10 mm vertically. The standard deviation of repeated analysis of the same image IOL rotation was $\pm 0.70^\circ$ and centration was ± 0.20 mm horizontally and ± 0.31 mm vertically.

Discussion

This study examined the repeatability of objective analysis of IOL rotation and centration and the effect of image quality. As expected iris feature and blood vessel clarity were related. While there were evidence of an improvement in imaging with time for blood vessel clarity, the reverse was found for iris features, perhaps due to the limited depth-of-focus of imaging systems. Some digital systems have an aperture control which can be reduced to enlarge the depth of focus to allow simultaneous imaging of the iris, conjunctiva and IOL toric markings. However, the illumination needs to be increased to compensate for the reduced aperture, which can cause discomfort to the patient, or the sensor gain increased, which can cause a 'grainy' image. The decrease in visibility of the toric IOL markings with time may also be related to fibrosis of the anterior capsule when the toric marking fall outside of the capsularhexis border. The clinical sites significantly differed in their ability to capture clear images of the IOL and anterior eye features and no site had consistently high performance emphasising the need for imaging training and support. Despite the low rotation of the Akreos AO IOL platform, apparent image rotation did increase with poorer rated image quality. This confirms the importance of high image quality for objective analysis of IOL rotation and gives support to the image quality metric devised.

The objective methodology allowed a repeatability of less than 1 ° in the assessment of the IOL rotation. Head rotation between measures was on average about 2 °, much reducing the variability of the measured IOL rotation when taken into account. This finding was consistent with a rotational study using fundus photography which found a mean rotation of 400 eyes to be 2.3 ± 1.7 °.³ Using the pupil or limbal centre to calculate changes in IOL centration gave an equivalent result, with repeatability of less about 0.1mm, an order of magnitude better than

subjective estimation. The pupil is not anatomically central to the limbus, particularly in the vertical meridian and the centre may vary with dilation. This may cause further variability in subjective estimation of IOL centration unless the reference anatomical feature is clearly defined.

In conclusion, objective analysis of digital retroillumination images at different post-op periods allows sensitive assessment of the stability of IOL rotation and centration. Eye rotation between images can lead to significant errors if not taken into account. The quality of the images also significantly affects the accuracy of objective assessment. The Akreos AO aspheric IOL with orientation marks is stable in the eye over 3 to 6 months following implantation.

References

- [1] Sun XY, Vicary D, Montgomery P, Griffiths M. Toric intraocular lenses for correcting astigmatism in 130 eyes. *Ophthalmology* 2000;107:1776-1781.
- [2] Mendicutte J, Irigoyen C, Ruiz M, Illarramendi I, Ferrer-Blasco T, Montes-Mico R. Toric intraocular lens versus opposite clear corneal incisions to correct astigmatism in eyes having cataract surgery. *J Cataract Refract Surg* 2009;35:451-458.
- [3] Viestenz A, Seitz B, Langenbucher A. Evaluating the eye's rotational stability during standard photography. Effect on determining the axial orientation of toric intraocular lenses. *J Cataract Refract Surg* 2005;31:557-561.
- [4] Ruhsurm I, Scholz U, Zehetmayer M, Hanselmayer G, Vass C, Skorpik C. Astigmatism correction with a foldable toric intraocular lens in cataract patients. *J Cataract Refract Surg* 2000;26:1022-1027.
- [5] De Silva DJ, Ramkissoon YD, Bloom PA. Evaluation of a toric intraocular lens with a Z-haptic. *J Cataract Refract Surg* 2006;32:1492-1498.
- [6] Chang DF. Early rotation stability of the longer Staar toric intraocular lens. *J Cataract Refract Surg* 2003;29:935-940.
- [7] Nguyen TM, Miller KM. Digital overlay technique for documenting toric intraocular lens axis orientation. *J Cataract Refract Surg* 2000;26:1496-1504.
- [8] Becker KA, Auffarth GU, Volcker HE. Evaluation of rotation and decentration of intraocular lenses. *Ophthalmologie* 2004;101: 600-603.
- [9] Bender L, Spalton DJ, Uyanonvara B, Boyce J, Heatley C, Jose R, Khan J. POCOman: New system for quantifying posterior capsule opacification. *J Cataract Refract Surg* 2004;30:2058-2063.
- [10] Weinand F, Jung A, Stein A, Pfutzner A, Becker R, Pavlovic S. Rotational stability of a single-piece hydrophobic acrylic intraocular lens: New method for high-precision rotation control. *J Cataract Refract Surg* 2007;33:800-803.

- [11] Patel CK, Ormonde S, Rosen PH Bron AJ. Postoperative intraocular lens rotation. A randomized comparison of plate and loop haptic implants. *Ophthalmology* 1999;106:2190-2196.
- [12] Shah GD, Praveen MR, Vasavada AR, Rampal NV, Vasavada VA, Asnani PK, Pandita D. Software-based assessment of postoperative rotation of toric intraocular lens. *J Cataract Refract Surg* 2009;35:413-418.
- [13] Tassignon MJ. Technology and needs for tomorrow's treatment of cataract - art. no. 64260E. *Ophthalmic Technologies XVII* 6426: E4260-E4260. Edited by Manns, F; Soederberg, PG; Ho, A; Stuck, BE; Belkin, M. presented at *17th Conference on Ophthalmic Technologies* in San Jose, CA, Jan 20-23, 2007.
- [14] Becker KA, Holzer MP, Reuland, AJ, Auffarth GU. Accuracy of lens power calculation and centration of an aspheric intraocular lens. *Ophthalmologe* 2006;103:873-876.
- [15] Perez-Torregrosa VT, Menezo JL, Harto MA, Maldonado MJ, Cisneros A. Digital system measurement of decentration of Worst-Fechner iris claw myopia intraocular lens. *J Refract Surg* 1995;11:26-30.

Table 1: Methods and findings of peer reviewed evaluations of toric IOLs. *Unknown* indicates information not apparent from publication.

Study (first Author)	Type of IOL	Eyes (Px)	Follow up period (months)	Analysis	Rotation \pm (SD)	Rotation description
Shimizu ¹⁰	Nidek Nt-98B	47 (47)	3	Image analysis no correction for head tilt	<i>Unknown</i>	21% > 30°
Grabow ¹¹	STAAR 4203TF	81 (?)	6+	<i>Unknown</i>	<i>Unknown</i>	5% \geq 40°
Ruhswurm ¹²	STAAR	37	20 \pm 17	Slit-lamp protractor	<i>Unknown</i>	21.6% >5°

	4203TF	(30)				2.7% $\geq 40^\circ$
Sun ⁵	STAAR 4203TF	130 (99)	3 (106 eyes)	<i>Unknown</i>	<i>Unknown</i>	25% $\geq 20^\circ$ 7% $> 40^\circ$
Leyland ¹³	STAAR 4203TF	22 (16)	4	Slit lamp protractor	8.9 \pm 11.6 °	22% $> 10^\circ$ 13.6% $> 20^\circ$ 9% $> 30^\circ$
Till ¹⁴	Mixed STAAR 4203TF & TL	100 (81) TF 63 TL 37	23 \pm 17 (weeks)	Image analysis no correction for head tilt	<i>Unknown</i>	14% $> 15^\circ$
Chang ¹⁵	STAAR 4203TF & 4203TL	TF 6 (4) TL 50 (37)	1	Slit lamp	<i>Unknown</i>	TF group 50% $\geq 30^\circ$ TL group 28% $> 5^\circ$ 10% $> 10^\circ$ 2% $> 15^\circ$
Jampaulo ¹⁶	STAAR 4203TF and 4203TL	25 (19)	Between 2 weeks and 26.2 months	Image analysis no correction for head tilt	1.36 \pm 1.85°	100% $\leq 5^\circ$
Chang ¹⁷	STAAR 4203TF and 4203TL AcrySof SN60T	90 TL80 TF10 100	1	Slit lamp protractor	5.56 \pm 8.49 3.35 \pm 3.41	27% $> 5^\circ$ 9% $> 10^\circ$ 3% $> 15^\circ$ 3.3% repositioned 10% $> 5^\circ$ 1% $> 10^\circ$

AcrySof SN60T FDA trial 2005	AcrySof SN60T	244	6	<i>Unknown</i>	3.4 ± 3.0	18.9% > 5 2.9% > 10 0.4% repositioned
Weinand ¹⁸	AcrySof SN60T	17	6	Image analysis with head rotation compensation	0.7 range 0.1 to 1.8	0% > 5
Bauer ¹⁹	AcrySof SN60T	53 (43)	4	Slit lamp vertical arm reading	3.5 ± 1.9	<i>Unknown</i>
Olaru ²⁰	AcrySof SN60T	32 (30)	2	<i>Unknown</i>	<i>Unknown</i>	9% > 5 3% > 30
Mendicute ²¹	AcrySof SN60T	30 (15)	3	Slit lamp beam axis	3.63 ± 3.11	19% > 5 3% > 10
Zuberbuhler ²²	AcrySof SN60T	44 (33)	Between 1 week and 3 months	Slit lamp integrated eye piece with axis measurement	2.2 ± 2.2	5% > 5
Dardzhikova ²³	AcrySof SN60T	111 (70)	6	<i>Unknown</i>	<i>Unknown</i>	7.8% > 5 4.5% > 10 1.8% > 20 2 repositions
Mendicute ⁶	AcrySof SN60T	20	3	Slit lamp integrated eyepiece with axis measurement	$3.53 \pm$ 1.97	5% > 5
Ruiz-Mesa ²⁴	AcrySof SN60T	32 (19)	6	Slit lamp integrated eyepiece with axis measurement	$0.91 \pm$ 1.77	3% > 5
De Silva ²⁵	MicroSII 6116TU	21 (14)	Between day 1 and 6 months	Slit lamp graticule	$5 \pm ?$	0% > 5
Dick ²⁶	MicroSII 6116TU	68 (48)	3	<i>Unknown</i>	<i>Unknown</i>	15% > 5

						1.5% >20
Gerten ²⁷	Custom IOL (600TW) Dr Schmidt	26 (24)	12-48	Slit lamp	<i>Unknown</i>	46% > 5 23% > 10

FIGURE LEGENDS

Figure 1: An image of a retroilluminated IOL, with the axis of a line joining the IOL orientation marks (dashed black line) normalised for any rotation of the eye by comparing to the axis of a line joining two consistent conjunctival vessels (solid black line) or iris features on opposite sides of the pupil margin. The centre of ovals overlaid to circumscribe the IOL optic edge (dashed red line), the pupil margin and the limbus (solid red line) were compared to determine the IOL centration.

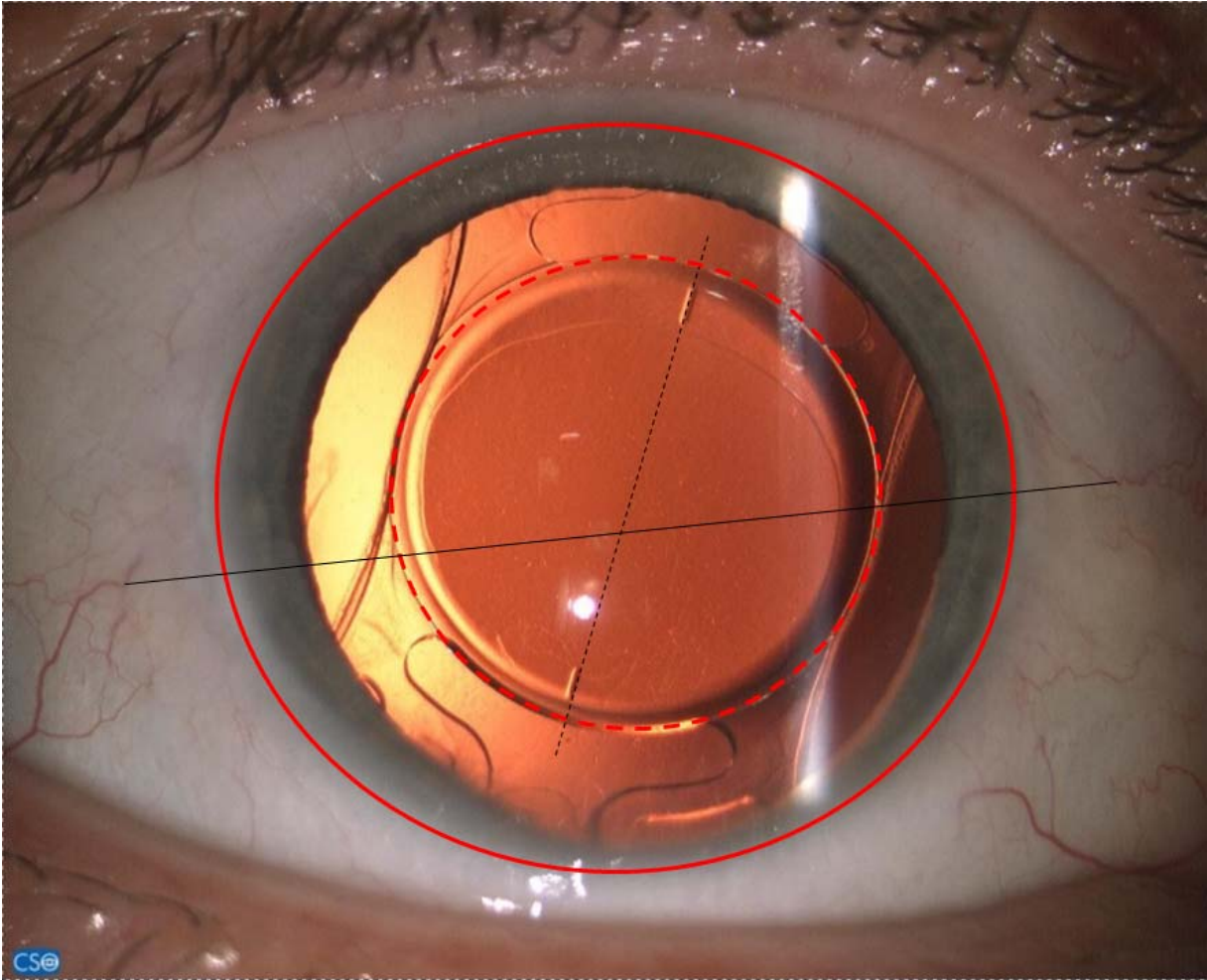


Figure 2: Rated image quality compared to apparent IOL rotation.

