

A quantitative analysis of optic nerve axons in elderly control subjects and patients with Alzheimer's disease

Anila B. Syed, Richard A. Armstrong, Christopher U.M. Smith

Vision Sciences, Aston University, Birmingham B4 7ET, United Kingdom

Folia Neuropathol. 2005; 43 (1): 1-6

Abstract

Objective: To study the density and cross-sectional area of axons in the optic nerve in elderly control subjects and in cases of Alzheimer's disease (AD) using an image analysis system.

Methods: Sections of optic nerves from control and AD patients were stained with toluidine blue to reveal axon profiles.

Results: The density of axons was reduced in both the center and peripheral portions of the optic nerve in AD compared with control patients. Analysis of axons with different cross-sectional areas suggested a specific loss of the smaller sized axons in AD, i.e., those with areas less than $1.99 \mu\text{m}^2$. An analysis of axons $>11 \mu\text{m}^2$ in cross-sectional area suggested no specific loss of the larger axons in this group of patients.

Conclusions: The data suggest that image analysis provides an accurate and reproducible method of quantifying axons in the optic nerve. In addition, the data suggest that axons are lost throughout the optic nerve with a specific loss of the smaller-sized axons. Loss of the smaller axons may explain the deficits in color vision observed in a significant proportion of patients with AD.

Key words: Alzheimer's disease, optic nerve, axons, size distribution, image analysis

Introduction

Alzheimer's disease (AD) is a neurodegenerative disorder of the central nervous system affecting approximately 1 in 10 of the population aged 65 or over. Disturbances of short-term memory, judgement, and emotion are characteristic of such patients. Patients with AD also exhibit a variety of ocular and visual problems [4] including abnormalities of color vision [7,8,20], eye movement [11,12,20,24], contrast sensitivity [23], motion perception, and complex visual functions such as reading and object recognition [7].

To attempt to explain the visual symptoms of patients with AD, pathological studies have been carried out on the retina [15], optic nerve [15], and visual cortex [2,3]. Gliosis, demyelination and increased densities of corpora amylacea have all been reported in optic nerves of elderly control subjects [13]. In addition, axon counts in the optic nerve decrease with age [10,16-18,21] with swelling and shrinking of individual axons [14]. In AD, the demonstration of axon loss in the optic nerve has been controversial. Some studies [15,25] have reported a loss of the larger-diameter axons while

Communicating author:

Richard A. Armstrong, Vision Sciences, Aston University, Birmingham B4 7ET, United Kingdom, fax +44 121 3334220, e-mail: R.A.Armstrong@aston.ac.uk

Table 1. Details of patients used in the study

Patient group	N	Sex ratio (M:F)	Mean age (years)	SD	Age range (years)
non-demented elderly	13	6:7	78.5	8.57	66-82
Alzheimer's disease	12	5:7	81.9	6.54	69-84

N = number of patients, M = male, F = female, SD = standard deviation

other studies have suggested that myelinated axons are unaffected [9].

The present study quantified axon densities and cross-sectional areas in the optic nerve using an image analysis system and had the following objectives: 1) to determine the reproducibility of axon counts made by an image analysis system compared with manual counts, 2) to compare axon densities in the center and periphery of the optic nerve in AD patients with non-demented elderly controls, and 3) to determine whether there was a preferential loss of the larger or smaller-sized axons in the central and peripheral regions of the nerve.

Materials and methods

Cases

Optic nerves from AD cases were obtained from the Brain Bank, Dept. of Neuropathology, Institute of Psychiatry, London, UK while optic nerves from non-demented elderly control cases were obtained from the Institute of Psychiatry and from the University of Birmingham Medical School (Table 1). Informed consent was given for the removal of all brain tissue according to the Declaration of Helsinki (1964). The control cases (n=13) had no neurological or psychiatric histories and were matched to the AD cases as closely as possible for gender and age. Post-mortem delay was less than 20 hours in each case. The AD cases (n=12) were clinically assessed and all fulfilled the 'National Institute of Neurological and Communicative Disorders and Stroke and Alzheimer's Disease and Related Disorders Association' (NINCDS/ADRDA) criteria for probable AD [27]. The histological diagnosis of AD was established by the presence of widespread neocortical senile plaques (SP) consistent with the 'Consortium to Establish a Registry of Alzheimer's Disease' (CERAD) criteria [22].

Histological methods

From each patient, a segment of the optic nerve was removed 4-5 mm in front of the optic chiasm. Tissue was embedded in epoxy-resin and 1-2 μm coronal sections cut and stained with toluidine blue to reveal the axon profiles.

Morphometric methods

The density and cross-sectional area of axons in the tissue sections were quantified using an image analysis system [26]. This system comprised a Carl Zeiss Photomicroscope fitted with a Hatachi Saticon color camera. The microscope was connected to an Apple Macintosh IICI computer. Computer images were analyzed using 'Image' software developed by NIH, Bethesda, USA (Available from: National Technical Information Service, Springfield, Virginia, USA; Part number: PB93-504868). Each section of the optic nerve was divided into four approximately equal quadrants. Two sample fields, each 1971 μm^2 in area were located within each quadrant, one as close as possible to the edge and the other to the center of the section. The image of each field was captured (Fig. 1A), a smoothing filter was applied and the contrast enhanced. Each axon was then outlined manually on the screen (Fig. 1B). A screen magnification of x8 was used to aid identification of axon profiles. Ambiguous structures were excluded at this stage and the outlines of the axons emphasized. The number of axons present in the field was counted and the myelinated cross-sectional area of each axon measured. Cross-sectional areas were quantified rather than diameters because axon profiles are commonly asymmetrical in shape. The size measurements of axons in the optic nerve were assigned to a number of area classes (0-0.99, 1-1.99, 2-2.99 μm^2 etc., up to a maximum area class of >11 μm^2).

Reproducibility of axon counts

To compare the reproducibility of axon counts made manually and by the image analysis system, ten microscopic fields were photographed at a magnification of x100 and then captured using the image analysis system. Duplicate counts of the numbers of axons were made manually from the photomicrographs and from the image analysis system. The reproducibility of the duplicate counts both within and between methods were analyzed using the intra-class correlation coefficient [5].

Analysis of axon counts and cross-sectional areas

The data were analyzed using analysis of variance (ANOVA) (SuperANOVA Software, Abacus Concepts Inc., Berkeley, CA 1989, USA). First, the density of axons per sample field in the center and periphery of the

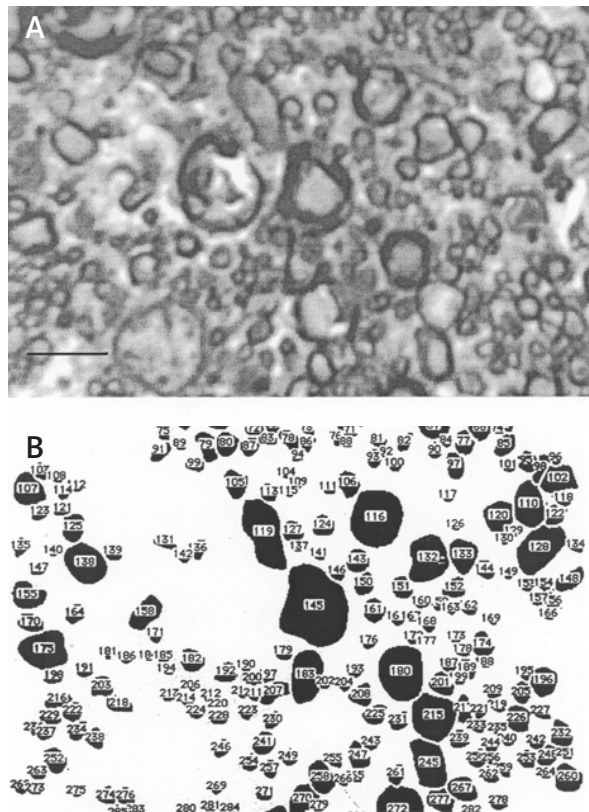


Fig. 1. Image analysis of axon profiles in a section of the optic nerve: A) Capturing the image on computer screen, B) Outlining the axons prior to measuring and counting. Magnification bar 5 μm

optic nerve in control and AD patients was analyzed by a two-factor, split-plot ANOVA with patient group as the major factor and region of the optic nerve as the subplot factor. Second, axons of different cross-sectional area were analyzed by a three-factor, split-split plot ANOVA with patient group as the major factor, area class of axons and location within the nerve being the subplot factors. Third, axons with larger cross-sectional areas ($>11 \mu\text{m}^2$) in the center and periphery of the nerve were analyzed separately using a two-factor, split-plot ANOVA with patient group as the major factor and size of axons as the subplot factor.

Results

The reproducibility of axon counts made manually and by image analysis is shown in Table 2. Image analysis counts ($r_1=0.99$) were considerably more reproducible than manual counts ($r_1=0.28$). In addition, agreement between sets of counts obtained by both methods varied considerably from image to image ($r=0.70$), 5/10 images showing good agreement and 5/10 poor agreement.

Axon counts made in the central and peripheral portions of the nerve in AD and elderly control subjects are shown in Fig 2. There was a reduction in

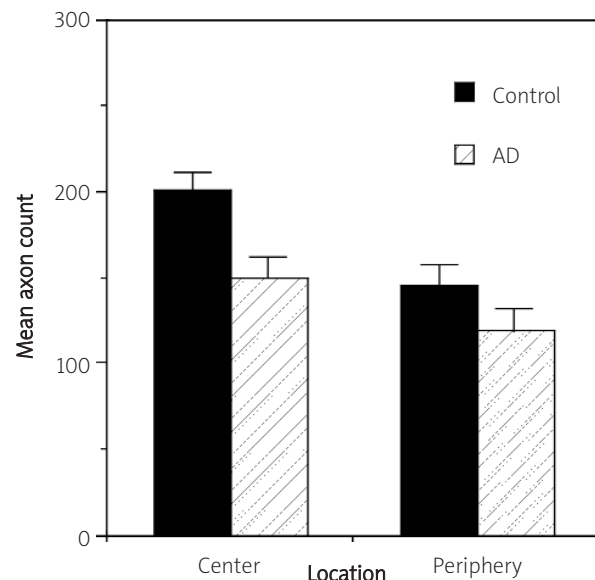


Fig. 2. Mean number of axons in the center and periphery of the optic nerve in elderly control subjects and patients with Alzheimer's disease. ANOVA: Patient group $F=9.64$ ($P<0.01$), Location $F=11.84$ ($P<0.01$), Interaction $F=1.13$ ($P>0.05$)

Table 2. Reproducibility of axon counts in 10 images of the optic nerve in an elderly control patient measured by manual counting and by image analysis

Image	Manual		Image analysis	
	First Count	Second Count	First Count	Second Count
1	102	187	192	192
2	173	169	167	167
3	148	138	144	144
4	190	201	191	190
5	155	148	142	142
6	200	199	198	200
7	206	147	195	195
8	146	129	149	146
9	185	176	160	160
10	142	135	135	135

Reproducibility of counts: Intra-class correlation coefficients (r_i), Manual method ($r_i=0.28$), image analysis method ($r_i=0.99$). Comparison of averaged counts between methods (Pearson's $r=0.70$).

axon counts in AD compared with elderly controls in the center and periphery of the nerve ($F=9.64$, $P<0.01$), the non-significant interaction ($F=1.13$, $P>0.05$) suggesting losses were similar in both portions of the nerve. Analysis of portions of nerve corresponding to the nasal and temporal visual fields of the retina also revealed similar losses of axons.

Mean counts of axons of different cross-sectional area per sample field are shown in Fig. 3. These data suggest a specific loss of the smaller sized axons in the center and periphery of the nerve, i.e., those with cross-sectional areas $<1.99 \mu\text{m}^2$. In addition, axons of larger cross-sectional area ($>11 \mu\text{m}^2$) were analyzed separately (Fig. 4). These data suggest a greater proportion of larger sized axons at the periphery of the nerve compared with the center. However, no significant difference in the proportions of large axons was observed in the center or periphery of the nerve in AD compared with controls.

Discussion

Estimation of axon densities may be influenced by a number of factors including age, gender, post-mortem

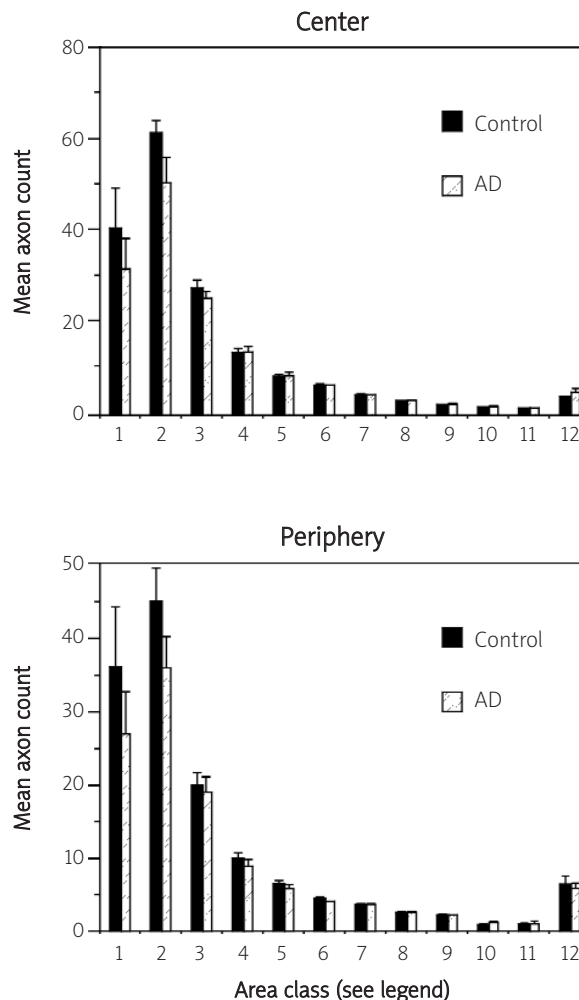


Fig. 3. Mean number of axons per sample field (Area classes: 1=0-0.99 μm^2 , 2=1-1.99 μm^2 , 3=2-2.99 μm^2 etc up to 12 $\geq 11 \mu\text{m}^2$), in the center and periphery of the optic nerve of elderly control subjects and patients with Alzheimer's disease (AD). ANOVA: Main effects; Patient group $F=6.19$ (DF 1,23; $P<0.05$), Location $F=5.56$ (DF 1,23; $P<0.05$), Area class $F=127.02$ (DF 11,442; $P<0.001$); Interactions: Patient group x Location $F=0.10$ (DF 1,23; $P>0.05$), Area class x Patient group $F=2.99$ (DF 11,442; $P<0.001$), Area class x location $F=2.57$ (DF 11,442; $P<0.001$); Three factor interaction $F=0.025$ (DF 11, 442; $P>0.05$)

delay, time to fixation, the image analysis system used, and the criteria employed to select or reject axon profiles. In the present study, patient groups were matched as closely as possible for age and sex. In

addition, no correlation has been observed between axon counts and time to fixation [17] although a significant post-mortem delay, i.e., greater than 20 hours, may have an influence on axon counts.

Image analysis counts of axons in the optic nerve were considerably more reproducible than manual counts. In addition, although there was a good agreement between counts made by both methods on images of very good quality, the agreement was poor between counts made on images of poorer quality. Hence, image analysis provides an accurate and reproducible method of quantifying axons of varying size in the optic nerve.

A significant reduction in the number of axons was observed in the optic nerve in AD patients compared with non-demented elderly control subjects. Axonal loss in the optic nerve in AD has been reported previously [15,25] but not in all studies [9]. The present data suggest a greater loss of the smaller-sized axons throughout the optic nerve in AD. This result contrasts with some previous reports that suggest it is primarily the larger-sized axons that are lost in AD [25]. It is possible that the proportion of the smallest axons may have been underestimated in some previous studies. Studies of the corpus callosum [1] suggest that axons less than 0.4 μm in diameter and amounting to 20% of the total axons are difficult to detect by conventional light microscopy. Studies employing image analysis may provide more accurate estimates of the densities of the smaller-sized axons. Alternatively, there may be subtypes of AD in which the degeneration affects preferentially, either the large or small axons. If the smaller-sized axons are affected in the optic nerve in AD, then the data suggest impairment of the parvocellular (P) visual pathway. This pathway is involved in the detection of fine details of the visual scene and with color vision [19]. Consistent with the involvement of the P-pathway, abnormalities of color vision have been observed in up to 50% of patients with AD [20].

Axon loss in the optic nerve in AD could be due to a disorder that directly affects the white matter tracts. An associated white matter disorder linked to cerebrovascular disease has been reported in 60% of patients with AD [6]. This disorder is characterized by a loss of axons and oligodendrocytes, demyelination, and a mild reactive astrocytic gliosis. Alternatively, loss of axons in AD could be secondary to neuronal degeneration. Hence, axon loss in the optic nerve

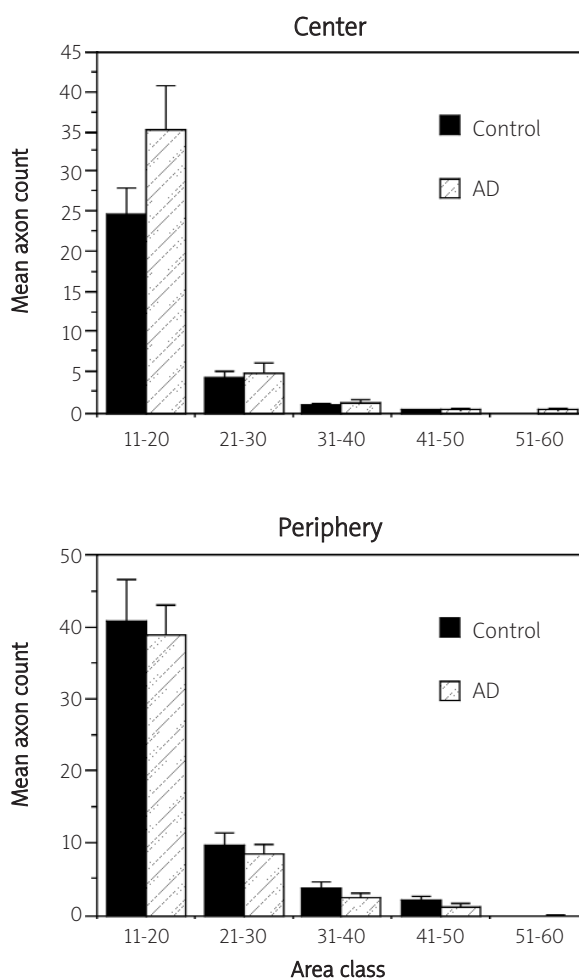


Fig. 4. Mean number of axons per sample field in the larger ($>11 \mu\text{m}^2$) size classes in the optic nerve of elderly control subjects and patients with Alzheimer's disease (AD). ANOVA main effects: Patient group $F=0.45$ ($P>0.05$), Location $F=5.76$ ($P<0.05$), Area class $F=170.98$ ($P<0.001$); Interactions: Patient group \times Location $F=1.16$ ($P>0.05$), Area class \times Patient group $F=1.25$ ($P>0.05$), Area class \times location $F=2.71$ ($P<0.05$); Three factor interaction $F=1.09$ ($P>0.05$)

could reflect loss of retinal ganglion cells [15] or degenerative changes within the visual cortex [3].

Acknowledgements

The assistance of the Brain Bank, Institute of Psychiatry, London and the University of Birmingham Medical School in providing post-mortem material for this study is gratefully acknowledged.

References

1. Aboitiz F, Scheibel AB, Zaidel E. Morphometry of the sylvian fissure and the corpus callosum with emphasis on sex differences. *Brain* 1992; 115: 1521-1541.
2. Armstrong RA, Nochlin D, Sumi SM, Alvord EC. Neuropathological changes in the visual cortex in Alzheimer's disease. *Neurosci Res Commun* 1990; 6: 163-171.
3. Armstrong RA. Visual field defects in Alzheimer's disease patients may reflect differential pathology in primary visual cortex. *Opt Vis Sci* 1996; 73: 677-682.
4. Armstrong RA, Syed AB. Alzheimer's disease and the eye. *Ophthal Physiol Opt (suppl. 1)* 1996; 16: S2-S8.
5. Bland JM, Altman DG. Measurement error and correlation coefficients. *BMJ* 1996; 313: 41-42.
6. Brun A, Englund E. A white matter disorder in dementia of the Alzheimer type: a pathoanatomical study. *Ann Neurol* 1986; 19: 253-262.
7. Cogan DG. Alzheimer syndromes. *Am J Ophthalmol* 1987; 104: 183-184.
8. Cronin-Golomb A, Corkin S, Rizzo JF, Cohen J, Growden JH. Visual dysfunction in Alzheimer's disease: Relation to normal aging. *Ann Neurol* 1991; 29: 41-52.
9. Davies DC, McCoubrie P, McDonald B, Jobst KA. Myelinated axon number in the optic nerve is unaffected by Alzheimer's disease. *Br J Ophthalmol* 1995; 79: 596-600.
10. Dolman CL, McCormick AQ, Drance SM. Aging of the optic nerve. *Arch Ophthalmol* 1980; 226: 213.
11. Fletcher WA. Ophthalmological aspects of Alzheimer's disease. *Curr Opin Ophthalmol* 1994; 5: 38-44.
12. Fletcher WA, Sharpe JA. Smooth pursuit dysfunction in Alzheimer's disease. *Neurol* 1988; 38: 272-277.
13. Giarelli L, Grandi G, Delendi M and Falconieri G. The pathology of the optic nerve in aging. *Metab Ped System Ophthalmol* 1989; 12: 61-63.
14. Godlewski A. Morphology of myelin fibres in corpus callosum and optic nerve of aging rats. *J Hirnforsch* 1991; 32: 39-46.
15. Hinton DR, Sadun AA, Blancks JC, Miller CA. Optic nerve degeneration in Alzheimer's disease. *N Eng J Med* 1986; 315: 485-487.
16. Johnson BM, Maio M, Sadun AA. Age-related decline of the human optic nerve axon populations. *Age* 1987; 10: 5.
17. Jonas JB, Muller-Bergh JA, Schlotzer-Schrehardt UM, Naumann GOH. Histomorphology of the human optic nerve. *Inv Ophth Vis Sci* 1990; 31: 736-744.
18. Jonas JB, Schmidt AM, Muller-Bergh JA, Schlotzer-Schrehardt UM, Naumann GO. Human optic nerve fiber count and optic disc size. *Invest Ophthalmol Vis Sci* 1992; 33: 2012-2018.
19. Kaplan E, Lee BB, Shapley RM. New views of primate retinal function. In: Osborne N and Chader J (eds). *Progress in Retinal Research*. Pergamon Press 1990; 273-335.
20. Mendez MF, Tomsak RL, Remler B. Disorders of the visual system in Alzheimer's disease. *Neurology* 1990; 40: 439-443.
21. Mikelberg FS, Drance SM, Schulzer M, Yidegiligne HM, Weis MM. The normal human optic nerve: axon count and axon diameter distribution. *Ophthalmology* 1989; 96: 1325-1328.
22. Mirra SS, Heyman A, McKeel D, Sumi SM, Crain BJ, Brownlee LM, Vogel FS, Hughes JP, van Belle G, Berg L. The consortium to establish a registry for Alzheimer's disease (CERAD). Part II. Standardization of the neuropathologic assessment of Alzheimer's disease. *Neurology* 1991; 41: 479-486.
23. Nissen MJ, Corkin S, Buoanno FJ, Growden JH, Wray SH, Bayer J. Spatial vision in Alzheimer's disease; general findings and a case report. *Arch Neurol* 1985; 42: 667-671.
24. Sadun AA, Borchert M, DeVita E, Hinton DR, Bassi CJ. Assessment of visual impairment in patients with Alzheimer's disease. *Am J Ophthalmol* 1987; 104: 113-120.
25. Sadun AA, Bassi CJ. Optic nerve damage in Alzheimer's disease. *Ophthalmology* 1990; 97: 9-18.
26. Syed AB, Armstrong RA, Smith CUM. Quantification of axonal loss in Alzheimer's disease: an image analysis study. *Alz Rep* 2000; 3: 19-24.
27. Tierney MC, Fisher RH, Lewis AJ, Zoritto ML, Snow WG, Reid DW, Nieuwstraten P. The NINCDS-ADRDA Work Group criteria for the clinical diagnosis of probable Alzheimer's disease: a clinicopathologic study of 57 cases. *Neurology* 1988; 38: 359-364.